

LACC/G-GOC-1001

Ph III Laparoscopic or Robotic Radical Hysterectomy vs Abdominal Hysterectomy in Early Stage Cervical Cancer

PI: Pedro Ramirez

Trial setting: Cervix, FIGO stage IA1, IA2, or IB1

Study Design: Randomized Phase III

Sponsor(s): None

Planned No. of patients: 740


Current accrual: 610 as of 04/26/17

Other important information: 27 sites

G-GOC

A Phase III Randomized Clinical Trial Comparing Laparoscopic or Robotic Radical Hysterectomy with Abdominal Radical Hysterectomy in Patients with Early Stage Cervical Cancer

Andreas Obermair, MD*, Val Gebski, MD, Michael Frumovitz, MD, MPH,
Pamela T. Soliman, MD, MPH, Kathleen M. Schmeler, MD, MPH, Charles Levenback, MD,
and Pedro T. Ramirez, MD



N=740

International Collaboration

End points:

DSF

Recurrence rate

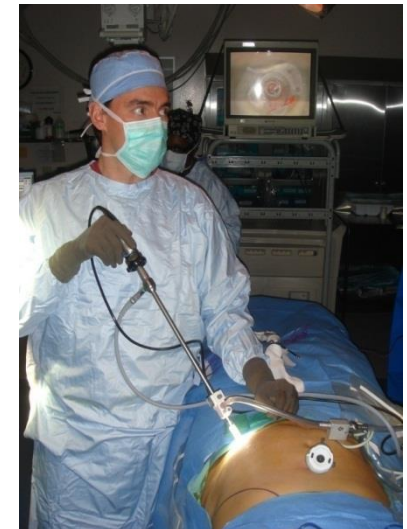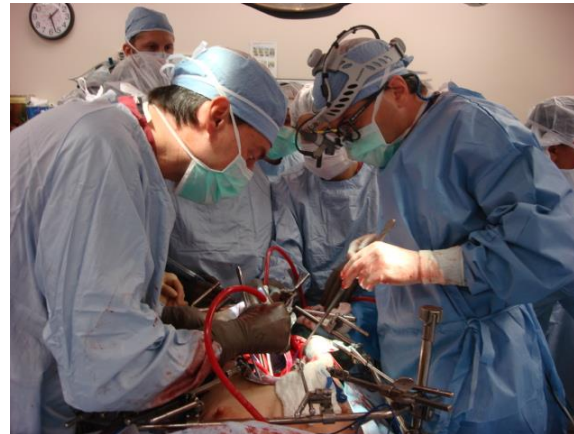Overall survival

Treatment-related morbidity

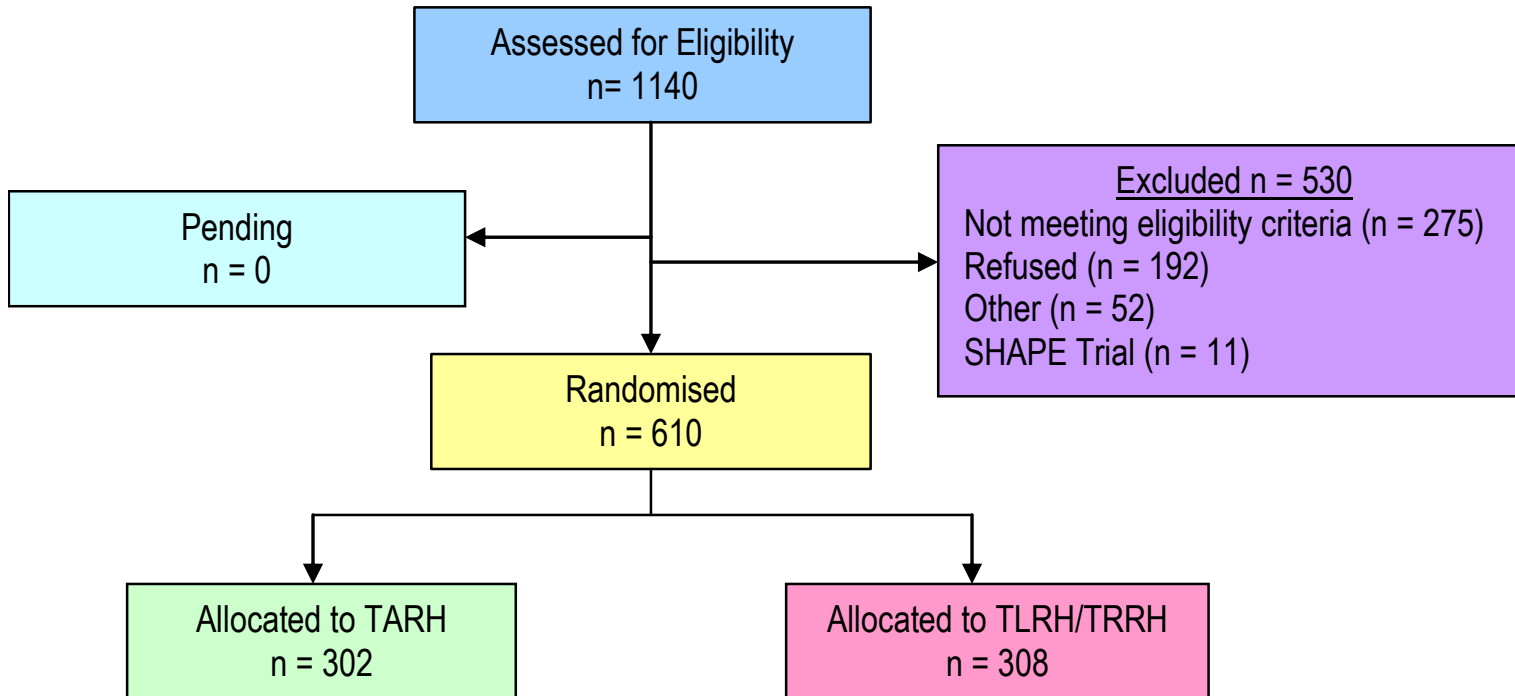
QOL

Lymphatic mapping feasibility


Total Sites : 27



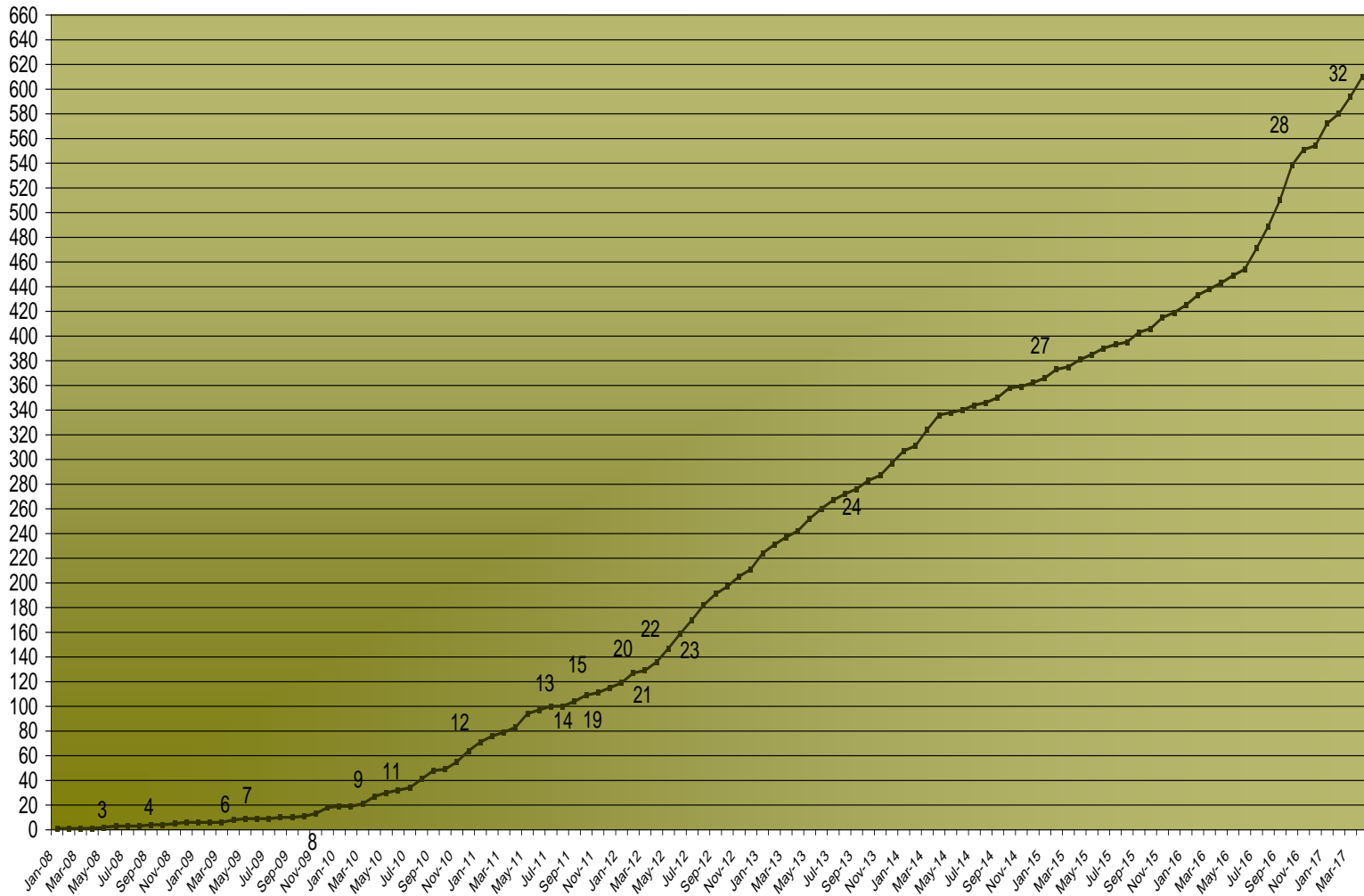
LACC Consort Statement as at 26th April 2017

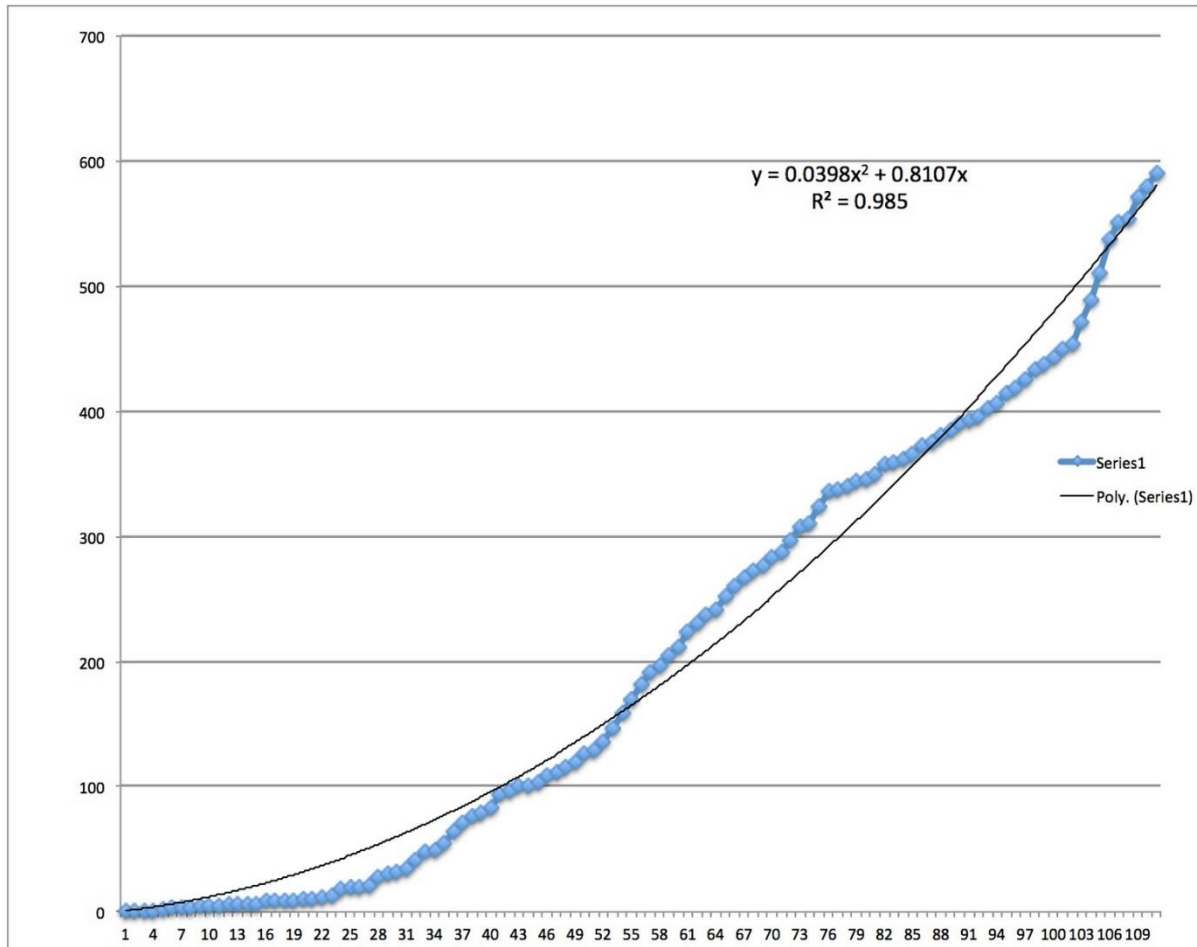


Accrual to Date As of April 26, 2017



Recruitment Tracker



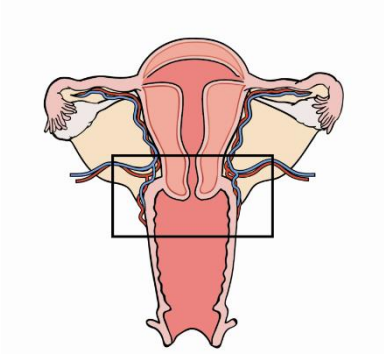



G-GOC

THE UNIVERSITY OF TEXAS
MD Anderson
~~Cancer~~ Center
Making Cancer History®

Ongoing Trials – status update

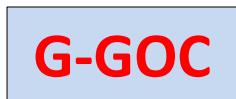
ConCerv/G-GOC-1002



Kathleen M. Schmeler, MD

Associate Professor

Department of Gynecologic Oncology & Reproductive Medicine



Conservative Surgery for Women with Low-risk, Early Stage Cervical Cancer

PI: Kathleen Schmeler

Trial setting: Cervix, FIGO stages IA2 or IB1

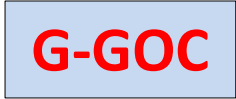Study Design: Phase II

Sponsor(s): M.D. Anderson Cancer Center

Planned No. of patients: 100

Current accrual: 73

Other important information:



ConCerv/G-GOC-1002

Inclusion Criteria:

- Squamous cell carcinoma of the cervix (any grade) or grade 1 or 2 adenocarcinoma of the cervix
- FIGO stage IA2 or IB1 disease
- Tumor diameter <2 cm on physical exam and on imaging studies
- No lymphovascular space invasion (LVSI) present on biopsy or previous cone
- Less than 10 mm of cervical stromal invasion
- Cone margins and endocervical curettage (ECC) specimen negative for invasive cancer, cervical intraepithelial neoplasia (CIN) CIN II, CIN III or adenocarcinoma-in-situ. (A negative margin is defined as no invasive cancer within 1.0mm of both the endocervical and ectocervical margins and no AIS or CIN II or CIN III at the inked or cauterized margin; one repeat cone and ECC permitted)
- Imaging PET scan, CT scan of the abdomen and pelvis, and/or MRI of the abdomen and pelvis must be performed and negative for metastatic disease within 12 weeks of enrollment



ConCerv/G-GOC-1002

- Future fertility desired:
Cone biopsy and pelvic node dissection
- Future fertility not desired:
Simple hysterectomy and pelvic node dissection

*SLN only optional



ConCerv/G-GOC-1002


- Sample size: 100 evaluable patients
- Stopping Rules:
 - Residual disease in the hysterectomy specimens of ≥ 3 patients
 - If ≥ 3 patients develop recurrent disease

ConCerv/G-GOC-1002

- MD Anderson, USA (K. Schmeler) 
- IDC, Colombia (G. Rendon) 
- INCAN, Mexico (D. Cantu) 
- Barretos, Brazil (G. Fontes) 
- INEN, Peru (A. Lopez) 
- Instituto de Ginecologia, Argentina (M. Riege) 
- Hospital Italiano, Argentina (M. Perrota) 
- Royal Women's, Australia (O. McNally) 
- Nebraska Methodist, USA (D. Crotzer) 
- Hospital Britanico, Argentina (A. Maya) 
- Chulalongkorn University, Thailand (T. Manchana) 
- Hospital Erasto Gaertner, Brazil (A. Tsunoda) 
- Instituto Brasileiro Controle de Cancer 

G-GOC

THE UNIVERSITY OF TEXAS
MD Anderson
~~Cancer Center~~
Making Cancer History®



ConCerv/G-GOC-1002

LACC Contacts

Pedro T. Ramirez, MD

peramire@mdanderson.org

Vanessa Behan

vanessa.behan@health.qld.gov.au

ConCerv Contacts

Kathleen M Schmeler

kschmele@mdanderson.org

Cindy Melendez

cvmelend@mdanderson.org