

## Gynecologic Cancer InterGroup Cervix Cancer Research Network



### Locally Advanced Cervical Cancer

- S.M.K F/47 referred to CDH with invasive moderately differentiated squamous cell carcinoma of the cervix.
- Initially diagnosed in July 2017 in Angola
- Received chemotherapy ?regimen in Angola from July to December 2017 as radiotherapy unavailable.
- First seen at CDH 13/06/2018
- Complained of backache, lower abdominal pain, PVD, abnormal PVB. RVD NR
- Rest of systemic review was normal
- General and systemic physical exam was normal

## Gynecologic Cancer InterGroup Cervix Cancer Research Network

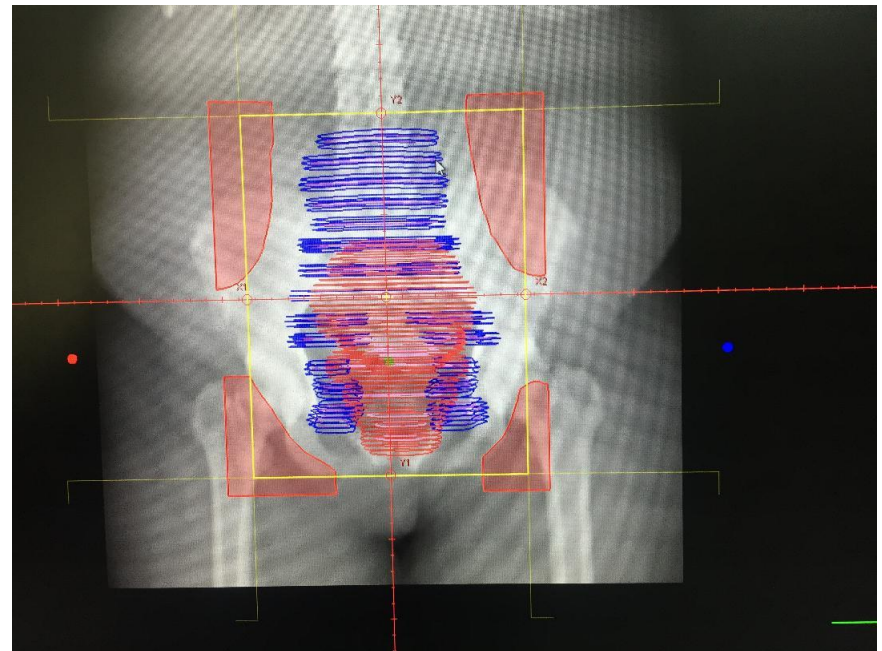


- Pelvic Exam: 4 X 3cm mass of the cervix
- Vagina free, Parametria free, Rectal mucosa free, uteral sacral ligament free
- Haematology, renal function normal
- CT scan-mass of cervix 5cm, with endometrial collection, no visceral or lymphnode mets, no hydronephrosis
- Staged as Cancer of the cervix stage IB2

## Gynecologic Cancer InterGroup Cervix Cancer Research Network



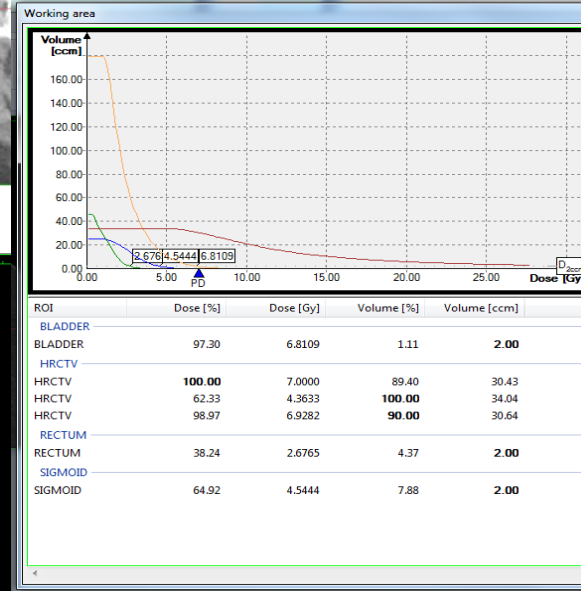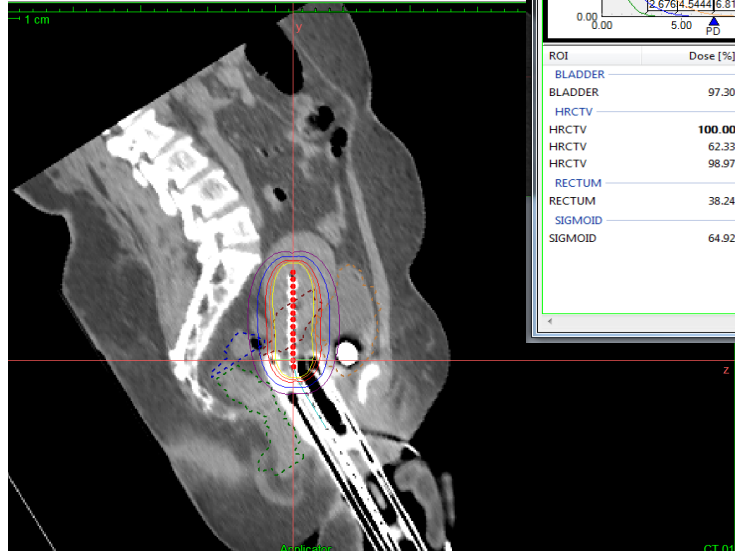
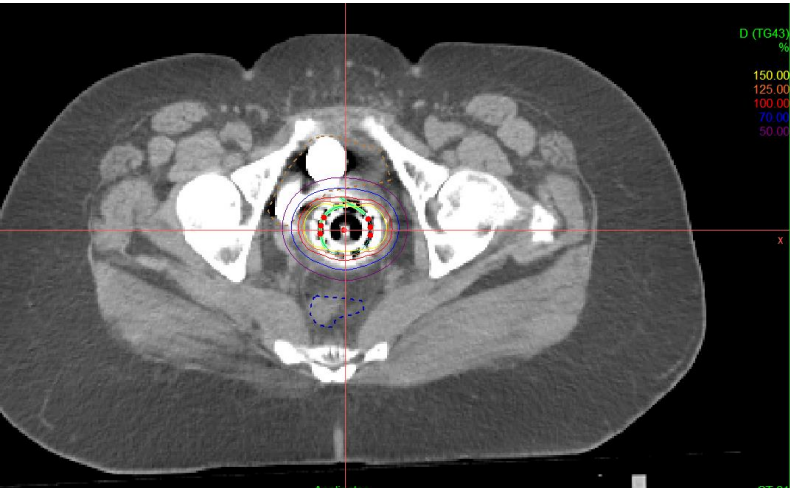
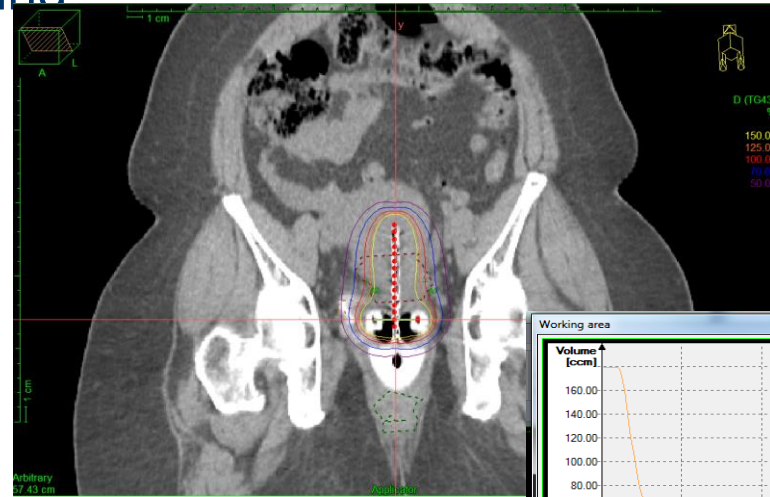
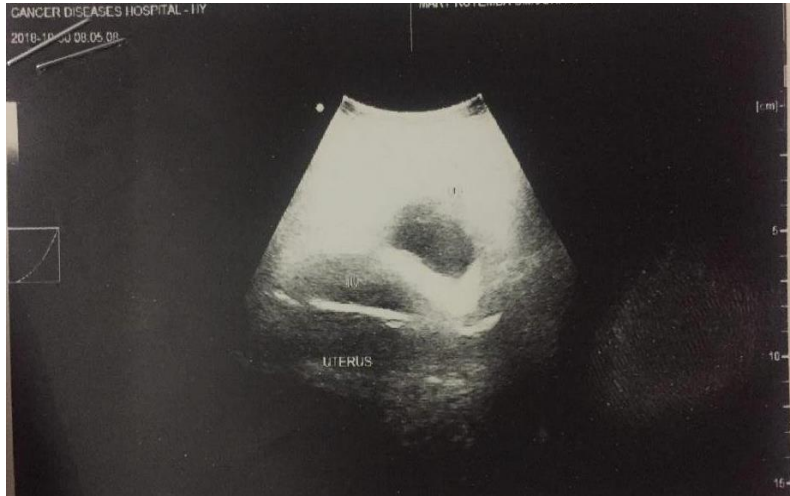- The patient received a radical course of concurrent chemoradiation as follows
- 46Gy/23 fractions/5weeks to the whole pelvis; APPA 10MV concomitantly with weekly cisplatin 40mg/m<sup>2</sup>, for 5 cycles.



# Gynecologic Cancer InterGroup Cervix Cancer Research Net



At brachy, had responded well to Rx. No parametrial, Vaginal involvement. Cervix smooth 3cm. 7Gy X 4 fractions image guided with CT based 3D treatment planning



## Gynecologic Cancer InterGroup Cervix Cancer Research Network



- On follow up, 3 months later she has NED

### FOR DISCUSSION

- Role of Neoadjuvant chemotherapy in locally advanced cervical cancer
- Role of salvage surgery in cases of poor response
- Contouring in 3D HDRB